

Nursing management of a patient with central retinal artery occlusion after percutaneous coronary intervention: a case report

Yan Zhang^{1#}, Yingtong Meng^{1#}, Tingting Zhang², Siyu Lu¹, Wenjian Ma¹

¹Cardiology Department II Ward I, Xinhua Hospital Affiliated to Shanghai Jiao Tong University School of Medicine, Shanghai, China; ²Department of Nursing, Xinhua Hospital Affiliated to Shanghai Jiao Tong University School of Medicine, Shanghai, China

Contributions: (I) Conception and design: Y Zhang, Y Meng, T Zhang; (II) Administrative support: T Zhang; (III) Provision of study materials or patients: All authors; (IV) Collection and assembly of data: All authors; (V) Data analysis and interpretation: None; (VI) Manuscript writing: All authors; (VII) Final approval of manuscript: All authors.

[#]These authors contributed equally to this work.

Correspondence to: Tingting Zhang, MD. Department of Nursing, Xinhua Hospital Affiliated to Shanghai Jiao Tong University School of Medicine, 1665 Jiangpu Road, Shanghai 200092, China. Email: zhangtingting02@xinhumed.com.cn.

Background: Central retinal artery occlusion (CRAO) is a rare but critical complication that might appear after percutaneous coronary intervention (PCI) with a high risk of blindness. The report on the nursing management of CRAO patients after PCI is rare.

Case Description: This patient is a 50-year-old female patient who was admitted to the Cardiovascular Department with repeated chest tightness. Initial assessment diagnosed as unstable angina and received a PCI. The patient complained of white patches in the left eye and blurred vision ten minutes after returning to the ward. The nurse found patient's symptoms at once and reported to the attending doctor for the first time of diagnosis. Fundus photography results confirmed the diagnosis of CRAO. The patient received high-flow oxygen inhalation and hyperbaric oxygen chamber treatment for days. Nitroglycerin sublingual administration and nitroglycerin intravenous micropump were used to improve retinal microcirculation. Finally, arterial thrombolysis was given to remove the embolism in the central retinal artery. The nurse played an important role in disease observation, risk identification, early detection, cooperation with doctors, post-thrombolytic care, and psychological care. The patient's left eye vision showed significant recovery, and she was discharged successfully. The patient reported gradual improvement in left-eye vision during the follow-up assessment.

Conclusions: This case report presents the interventions taken by nurses in early detection and care for a CRAO patient after PCI and expands the literature describing nursing management for patients with postoperative complications of PCI.

Keywords: Percutaneous coronary intervention (PCI); central retinal artery occlusion (CRAO); ophthalmologic nursing; thromboembolism; case report

Received: 25 March 2024; Accepted: 22 August 2024; Published online: 06 November 2024.

doi: 10.21037/acr-24-66

View this article at: <https://dx.doi.org/10.21037/acr-24-66>

Introduction

Background

Coronary angiography and percutaneous coronary intervention (PCI) are widely applied in the evaluation of patients with coronary artery disease (1). Although

PCI has significant therapeutic effects, it also has adverse complications (2) such as acute vessel closure, perforation, coronary stent infection and several other complications potentially leading to myocardial infarction, stroke, emergency surgery, and even death. Central retinal artery occlusion (CRAO) is one of the most severe complications

caused by obstruction of the central retinal artery, commonly due to emboli originating from atheromatous plaques in the cardiac valves and carotid arteries, resulting in retinal ischemia (3,4). Occlusion at any site from the common carotid artery to the intraretinal arterioles causes corresponding retinal ischemia.

Rationale and knowledge gap

CRAO may occur in patients after PCI, which is an ophthalmic emergency leading to retinal hypoxia, degeneration, necrosis, and even blindness. CRAO is not common but dangerous in patients after PCI. A previous study showed that fewer than 20% of patients regain functional visual acuity in their affected eye (5). And the phenotypic characteristic of CRAO is painless. And meanwhile, CRAO patients are burdened with some thrombophilic risk factors. Dziedzic *et al.*'s study showed that obesity, overweight, hypercholesterolemia, antiphospholipid antibodies, deficiencies in protein C activity and free protein S levels, factor V Leiden, and hyperhomocysteinemia were all thrombophilic risk factors of CRAO (6). Moreover, a previous study suggested that CRAO was related to vascular endothelial injury and left ventricular diastolic dysfunction (7). Therefore, nurses' early identification of high-risk populations and early nursing management for patients with early symptoms

as soon as possible are crucial for restoring the blood circulation in the central retinal artery and enabling patient to achieve better prognoses. However, there are few reports of successful rescue of patients with CRAO.

Objective

Herein, we provide the care considerations of the patient for cardiology nurses. This case report broadens the view about nursing interventions for patients with CRAO after PCI. We present this case in accordance with the CARE reporting checklist (available at <https://acr.amegroups.com/article/view/10.21037/acr-24-66/rc>).

Case presentation

Patient information

A female patient aged 50 years old was admitted to our hospital with repeated chest tightness and discomfort for over 2 years, aggravated for 1 week, and diagnosed as 'unstable angina pectoris'. The patient had a previous history of diabetes and cardiovascular diseases. She underwent coronary angiography + PCI in our hospital in 2016 and denied any family history.

Clinical findings

Initial assessments showed that elevated blood levels of total serum cholesterol [7.61 mmol/L (2.9–6.0 mmol/L)], low-density lipoprotein cholesterol [5.81 mmol/L (3.0–6.0 mmol/L)] and glycosylated hemoglobin 6.30%; baseline vital signs included body temperature, 36 °C; heart rate, 76/min; blood pressure, 132/60 mmHg; respirations, 18/min; oxygen saturation as measured by pulse oximetry, 96%; electrocardiogram (ECG) showed sinus rhythm. Diagnostic coronary angiogram revealed 99% stenosis at proximal left circumflex artery (LCX) and 90% stenosis at distal LCX. The interventional cardiologist stented the culprit lesion in the LCX with a single stent and a drug-eluting stent. Good angiographic flow was organized well in post-stent dilatation.

However, the patient complained of white patches in her left eye, blurred vision, and denied discomfort of eye soreness and pain after arriving at the ward in ten minutes. Physical examination: both eyes had a positive reflex to light (+), and no obvious congestion of the conjunctiva was observed. After half an hour, the patient complained of a

Highlight box

Key findings

- The nursing care plan for central retinal artery occlusion (CRAO) after percutaneous coronary intervention (PCI) should include psychological care and clinical nurse training to ensure optimal outcomes.

What is known and what is new?

- CRAO is a severe complication after PCI with a short treatment time window risk factors identification and quickly identifying the symptoms and causes of CRAO can help doctors grasp the treatment window.
- The nursing care plan for CRAO after PCI should include psychological care and clinical nurse training to ensure optimal outcomes. Psychological care by nurses can help the recovery of vision in CRAO patients.

What is the implication, and what should change now?

- We need more training of clinical nurses on the pathogenesis, clinical symptoms, and treatment measures of CRAO after PCI, in order to reduce complications.

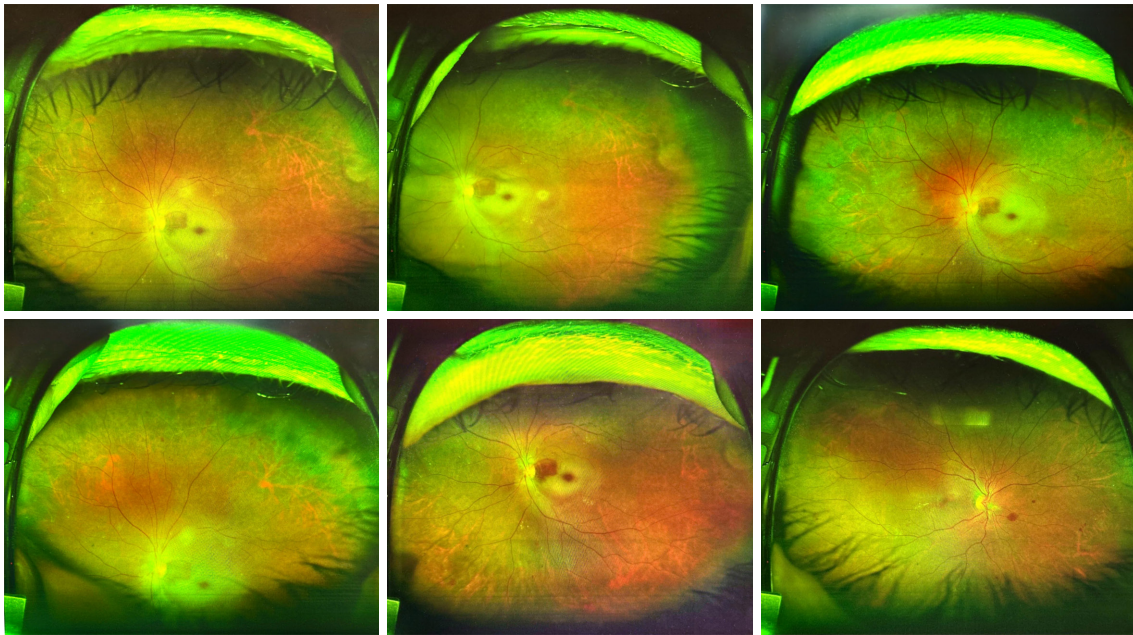


Figure 1 The result of fundus photography (cherry red spot).

worsening loss of vision in her left eye. The uncorrected distance visual acuity (UDVA) of her left eye was hand motion (HM) and finger counting (FC) at 5 cm. However, no abnormalities were found in the head CT scan.

Diagnosis

Fundus examination: at 8 o'clock on the following day, fundus photography and optical coherence tomography (OCT) revealed that the left pupil was moderately dilated, with positive relative incoming pupil defects. The superior branches of the retinal artery existed multiple emboli or Hollenhorst plaque. Optomap imaging showed that the surrounding retina whitened which increased the contrast with the fovea, making the fovea show a cherry red spot (*Figure 1*). Optomap imaging used the Daytona (P200T) device which is a scanning laser ophthalmoscope (SLO) with two scanning laser wave lengths of green (532 nm) and red (633 nm) and the examination duration was 2.3 min. The diagnosis was CRAO in the left eye.

Interventions

When the patient first complained of slight blurred vision in the left eye, the nurse conducted preliminary measurements of vital signs and vision to the patient and

found no abnormalities. Therefore, it is preliminarily considered that the patient may have side effects due to the long-term use of aspirin, clopidogrel, and anticoagulant therapy such as heparin sodium during surgery. After informing the doctor, the nurse maintained the original treatment and observed changes in the condition. Half an hour later, the patient complained of an aggravation in blurred visual acuity. After being diagnosed by CRAO through relevant examinations, the nurse immediately gave some treatments such as high-flow oxygen inhalation, massaging the eyeballs; nitroglycerin sublingual administration to dilate blood vessels and improve retinal microcirculation; 0.9% NS 49 mL + nitroglycerin 5 mg 7.5 mL/h micro pump intravenous infusion to increase the efficacy of vasodilation. Furthermore, the patient received an individual emergency hyperbaric oxygen chamber for hyperbaric oxygen treatment, but no significant improvement after the treatments. According to the OCT examination results, emergency arterial thrombolysis was performed immediately. After the surgery, the patient was anxious and depressed. The nurse provided her with a series of psychological care measures.

On follow-up 6 months postoperatively, the patient was doing well, disease-free with clear vision and no chest tightness or pain. The FC was 50 cm in her left eye.

All procedures performed in this study were in

accordance with the ethical standards of the Ethics Committee of Xinhua Hospital Affiliated to Shanghai Jiao Tong University School of Medicine (Approval No. XHEC-D-2024-053) and with the Helsinki Declaration (as revised in 2013). Written informed consent was obtained from the patient for the publication of this case report and accompanying images. A copy of the written consent is available for review by the editorial office of this journal.

Discussion

Key findings

This case report described a 50-year-old woman who developed blurred vision ten minutes after PCI. After the early detection by nurses and timely handling by doctors, the patient's vision recovered well and was discharged to home. During this process, the nurses' quick identification helped the doctor grasp the treatment window, and the careful psychological care provided by nurses after the onset of the illness accelerated the recovery process.

This article for the first time described the onset, treatment, and nursing process of a CRAO patient after PCI from a nursing perspective. Compared to the studies by Hsien *et al.* (8) and Filatov *et al.* (9) this study emphasized the importance of early emergency care and later psychological care by nurses for the recovery of vision in CRAO patients, and advocated for more training of clinical nurses on the pathogenesis, clinical symptoms, and treatment measures of postoperative complications such as CRAO after PCI, in order to reduce the adverse prognosis caused by complications.

PCI: an effective but risky intervention

Coronary angiogram and subsequently PCI have matured rapidly and are essential diagnosis and treatment procedures for coronary heart disease patients which include stable or unstable angina, acute myocardial infarction, ST-elevation myocardial infarction (STEMI), and non-ST-segment elevation myocardial infarction (NSTEMI). However, PCI results in a significant risk of embolization including arrhythmia, extension of left main stem (LMS) artery, hypokinetic wall, and presence of intramural thrombus and ocular vessels. The studies revealed that the incidence of PCI-associated vascular complications was 2% to 6% (10,11). Although PCI is an effective treatment method, there is still a specific incidence of complications.

CRAO: a severe complication after PCI with a short treatment time window

The post-PCI CRAO is rare but severe, with an overall incidence of approximately 6.33% (8). Furthermore, individuals with advanced age, hypertension, arrhythmia, LMS, etc. have significantly higher risk of post-PCI CRAO. However, the mechanism by which PCI may cause retinal artery occlusion has not been elucidated. A study explained that the retinal ischemia might be caused by embolic rather than hypoperfusion (12). Risk factors related to higher rates of CRAO included diabetic retinopathy, aortic insufficiency, atrial myxoma, hypercoagulability, and carotid artery stenosis (13).

Acute treatment of retinal artery occlusion remains controversial (14). The overall goal of the treatment is reperfusion of the blocked retinal vessels especially within six hours, since retinal ischemic damage after 240 min is usually irreversible (8). There was evidence showing that the occlusion within 97–240 min might produce a variable degree of damage caused by tissue infarction. The damage can be reversed and reduced by reperfusion of blocked retinal vessels, only if it is done within a certain limit (3). A retrospective observational study showed that the patients treated either conservatively or with intravenous thrombolysis (IVT) within 4.5 h may lead to a favorable outcome (15).

Ocular massage, oxygen inhalation, antiplatelet and heparin therapy, intraocular pressure reduction, and isosorbide dinitrate sublingual administration are the conventional treatment methods. However, a previous study showed that these therapies might not only be ineffective but even harmful to the disease course (16). Other reported successful treatment methods include isovolumic hemodilution; intravenous steroids to reduce vascular endothelial; hyperbaric oxygen; surgical embolectomy; Nd:yttrium aluminum garnet (YAG) laser arteriotomy and embolectomy; and intraarterial fibrinolysis delivered directly into the ophthalmic artery (17). All the above treatment methods have not been confirmed to be effective. Within six hours of symptoms onset, using local intra-arterial fibrinolysis is widely accepted by clinicians for CRAO treatment (16). Therefore, treatments for CRAO symptoms are not yet unified. Awareness and swift recognition may help to identify the essence of the issue and prevent further important organ damage or recurrence.

In summary, the nurse should identify high-risk groups based on some risk factors and carry out targeted prevention and management. In addition, nurses must understand that

there is currently no unified and effective treatment method for CRAO. Also, the treatment time window for CRAO may be as short as six hours and if the treatment exceeds six hours, it will cause irreversible damage to vision. Therefore, we need to respond quickly and cooperate with the doctors' treatment choices.

Implications for post-PCI nursing

Risk factors identification

Essential aspects of CRAO management after PCI are recognition of risk factors and early signs and symptoms, correlation of assessment findings with fundus examination, and differentiation of CRAO from other conditions with similar symptoms (18). Our patients had multiple risk factors for CRAO after PCI, including coronary heart disease, diabetes, and hyperlipidemia. Device stimulation, anticoagulant use, and emotional stress during PCI can lead to atherosclerotic plaque shedding or small thrombosis. All these factors may contribute to embolic and monocular vision loss. Furthermore, the patient's blindness is sudden and painless shortly after PCI. Therefore, paying attention to patient complaints in high-risk patients is vital for reducing the occurrence of ocular complications. In addition, the patient's condition usually occurred at night, when nurses were tired and easy to slack off (19). Therefore, nurses should pay attention to visual complaints, and strengthen the inspection and observation of condition.

Quickly identifying symptoms and causes, grasping the treatment window

The timing of the diagnosis and initiation of treatment is the key to the prognosis for these patients. Therefore, it is necessary to be able to identify and respond to symptoms immediately after they appear. The nurse must be able to identify the patient's symptoms in a timely manner and inform the doctor. A systematic review of CRAO revealed that 12 to 15 minutes of complete CRAO might contribute to irreversible ganglion cell death (20). Because of the extremely short treatment time window for CRAO, nurses should accurately identify the symptoms and report them to doctors as soon as possible. Although the optimal treatment for CRAO is controversial, the patients in our case received correct and timely treatment such as immediate digital ocular massage, oxygen supplemental, nitroglycerin sublingual administration, and intravenous

injection. All therapies were aimed at restoring retinal perfusion/oxygenation. A literature review recommended supplemental oxygen for any patient presenting within 24 hours of vision loss with signs and symptoms that cause concern for CRAO because of the minimal risk associated with oxygen therapy (21). If available, hyperbaric oxygen therapy should be considered. However, the benefits of conservative therapies are limited compared with the natural course of disease. Therefore, our clinical team immediately changed the treatment plan and chose arterial thrombolysis therapy, because studies showed that early administration of local intra-arterial fibrinolysis shows promise.

Taking measures to improve anxiety symptom

Anxiety symptoms in patients who suffered sudden vision loss appear to be pronounced, as do symptoms of depression and posttraumatic stress disorder. In addition, emotional stress was the risk factor of CRAO after PCI. So, nurses need to provide targeted psychological care for patients based on their mental symptoms. In this case, nurses used the Generalized Anxiety Disorder 7-item Scale (GAD-7) to evaluate the patient's psychological state, and the patient scored 8 points, indicating mild anxiety disorder (22). Therefore, psychological care for the patient was critical. A previous study showed that cognitive behavioral therapy was an effective treatment for anxiety and depression (23). In this case, our nurse first used videos to demonstrate knowledge about PCI and CRAO, in order to minimize or even eliminate patients' negative thoughts about this disease. Then, our nurse guided the patient in relaxation training methods such as relaxation mental imagery training, mindfulness, and counting meditation. After the intervention, the patient's anxiety score was measured again, and the GAD-7 score decreased to 5 points.

Conclusions

In conclusion, CRAO is a rare but critically dangerous complication of PCI. The risk of CRAO needs to be discussed in cases. In this case, the role of the nurse was to identify risks, discover abnormal situations, and provide postoperative physical and mental care for the patient. Moreover, cooperation with doctors was also important to the medical treatment of CRAO. The lessons gained from this experience led to the formation of several recommendations for future CRAO patient care.

Acknowledgments

We would like to thank all the participants who contributed to the study.

Funding: This study was supported by Shanghai Hospital Development Center: Three-year Action Plan to Promote Clinical Skills and Innovation in Municipal Hospitals (SHDC2022CRS009B); Shanghai Jiao Tong University School of Medicine: Nursing Development Program (SJTUHLXK2022); and Xin Hua Hospital Affiliated to Shanghai Jiao Tong University School of Medicine: Nursing Development Program (Xhlxm006).

Footnote

Reporting Checklist: The authors have completed the CARE reporting checklist. Available at <https://acr.amegroups.com/article/view/10.21037/acr-24-66/rc>

Peer Review File: Available at <https://acr.amegroups.com/article/view/10.21037/acr-24-66/prf>

Conflicts of Interest: All authors have completed the ICMJE uniform disclosure form (available at <https://acr.amegroups.com/article/view/10.21037/acr-24-66/coif>). The authors have no conflicts of interest to declare.

Ethical Statement: The authors are accountable for all aspects of the work in ensuring that questions related to the accuracy or integrity of any part of the work are appropriately investigated and resolved. All procedures performed in this study were in accordance with the ethical standards of the Ethics Committee of Xinhua Hospital Affiliated to Shanghai Jiao Tong University School of Medicine (Approval No. XHEC-D-2024-053) and with the Helsinki Declaration (as revised in 2013). Written informed consent was obtained from the patient for the publication of this case report and accompanying images. A copy of the written consent is available for review by the editorial office of this journal.

Open Access Statement: This is an Open Access article distributed in accordance with the Creative Commons Attribution-NonCommercial-NoDerivs 4.0 International License (CC BY-NC-ND 4.0), which permits the non-commercial replication and distribution of the article with the strict proviso that no changes or edits are made and the original work is properly cited (including links to both the formal publication through the relevant DOI and the license). See: <https://creativecommons.org/licenses/by-nc-nd/4.0/>.

References

1. Hoole SP, Bambrough P. Recent advances in percutaneous coronary intervention. *Heart* 2020;106:1380-6.
2. Kandan SR, Johnson TW. Management of percutaneous coronary intervention complications. *Heart* 2019;105:75-86.
3. Shaban A, Leira EC. Neurologic complications of heart surgery. *Handb Clin Neurol* 2021;177:65-75.
4. Brown GC, Magargal LE. Central retinal artery obstruction and visual acuity. *Ophthalmology* 1982;89:14-9.
5. Ter Schiphorst A, Gaillard N, Dargazanli C, et al. Symptomatic isolated internal carotid artery occlusion with initial medical management: a monocentric cohort. *J Neurol* 2021;268:346-55.
6. Dziedzic R, Zaręba L, Iwaniec T, et al. High prevalence of thrombophilic risk factors in patients with central retinal artery occlusion. *Thromb J* 2023;21:81.
7. Dropiński J, Dziedzic R, Kubicka-Trzaska A, et al. Central Retinal Artery Occlusion Is Related to Vascular Endothelial Injury and Left Ventricular Diastolic Dysfunction. *J Clin Med* 2022;11:2263.
8. Hsien YM, Mustapha M, Hamzah JC, et al. Why can't I see after my heart is fixed: a case series of ocular complications after cardiac intervention. *BMC Ophthalmol* 2016;16:32.
9. Filatov V, Tom D, Alexandrakis G, et al. Branch retinal artery occlusion associated with directional coronary atherectomy after percutaneous transluminal coronary angioplasty. *Am J Ophthalmol* 1995;120:391-3.
10. Bricker RS, Valle JA, Plomondon ME, et al. Causes of Mortality After Percutaneous Coronary Intervention. *Circ Cardiovasc Qual Outcomes* 2019;12:e005355.
11. Monteleone PP, Yeh RW. Management of Complications. *Interv Cardiol Clin* 2016;5:201-9.
12. Raphael J, Moss HE, Roth S. Perioperative Visual Loss in Cardiac Surgery. *J Cardiothorac Vasc Anesth* 2019;33:1420-9.
13. Calway T, Rubin DS, Moss HE, et al. Perioperative Retinal Artery Occlusion: Risk Factors in Cardiac Surgery from the United States National Inpatient Sample 1998-2013. *Ophthalmology* 2017;124:189-96.
14. Schumacher M, Schmidt D, Jurklics B, et al. Central retinal artery occlusion: local intra-arterial fibrinolysis versus conservative treatment, a multicenter randomized trial. *Ophthalmology* 2010;117:1367-75.e1.
15. Raber FP, Gmeiner FV, Dreyhaupt J, et al. Thrombolysis in central retinal artery occlusion: a retrospective observational study. *J Neurol* 2023;270:891-7.
16. Li X, Chen T, Li Y, et al. Improved visual outcomes of

- central retinal artery occlusion with local intra-arterial fibrinolysis beyond the conventional time window. *J Thromb Thrombolysis* 2024;57:503-11.
17. Chronopoulos A, Schutz JS. Central retinal artery occlusion-A new, provisional treatment approach. *Surv Ophthalmol* 2019;64:443-51.
 18. Mac Grory B, Schrag M, Biousse V, et al. Management of Central Retinal Artery Occlusion: A Scientific Statement From the American Heart Association. *Stroke* 2021;52:e282-94.
 19. Imes CC, Tucker SJ, Trinkoff AM, et al. Wake-up Call: Night Shifts Adversely Affect Nurse Health and Retention, Patient and Public Safety, and Costs. *Nurs Adm Q* 2023;47:E38-53.
 20. Tobalem S, Schutz JS, Chronopoulos A. Central retinal artery occlusion - rethinking retinal survival time. *BMC Ophthalmol* 2018;18:101.
 21. Murphy-Lavoie H, Butler F, Hagan C. Central retinal artery occlusion treated with oxygen: a literature review and treatment algorithm. *Undersea Hyperb Med* 2012;39:943-53.
 22. Spitzer RL, Kroenke K, Williams JB, et al. A brief measure for assessing generalized anxiety disorder: the GAD-7. *Arch Intern Med* 2006;166:1092-7.
 23. Zhang A, Borhneimer LA, Weaver A, et al. Cognitive behavioral therapy for primary care depression and anxiety: a secondary meta-analytic review using robust variance estimation in meta-regression. *J Behav Med* 2019;42:1117-41.

doi: 10.21037/acr-24-66

Cite this article as: Zhang Y, Meng Y, Zhang T, Lu S, Ma W. Nursing management of a patient with central retinal artery occlusion after percutaneous coronary intervention: a case report. *AME Case Rep* 2024.